

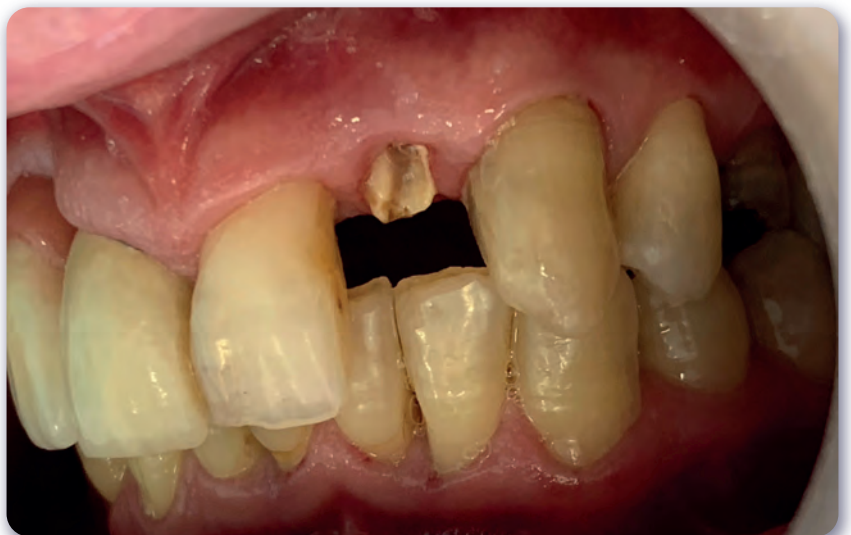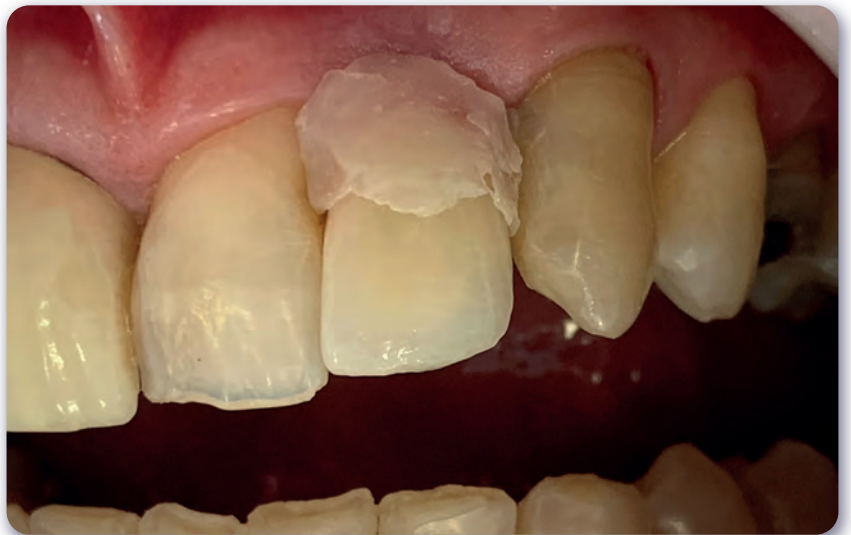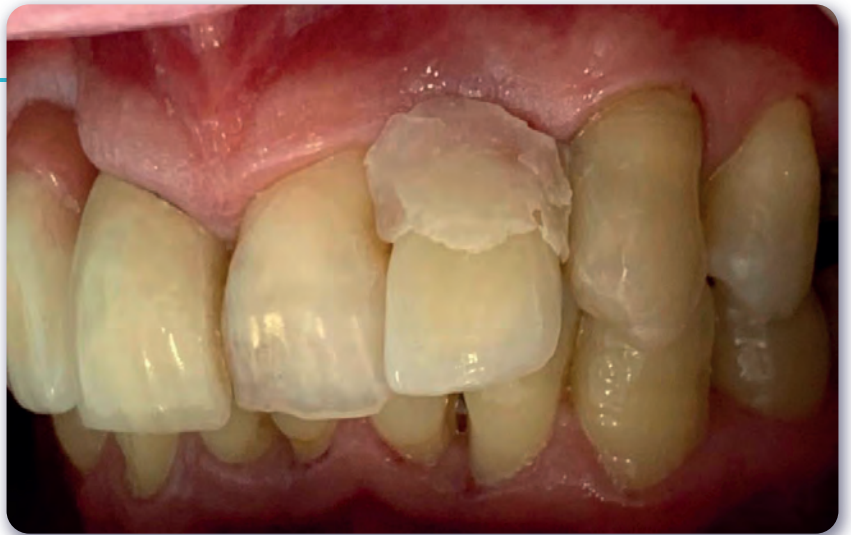CLINICAL CASE II

IMMEDIATE IMPLANTATION

using Biomed implant / GIH® system
on a maxillary lateral incisor

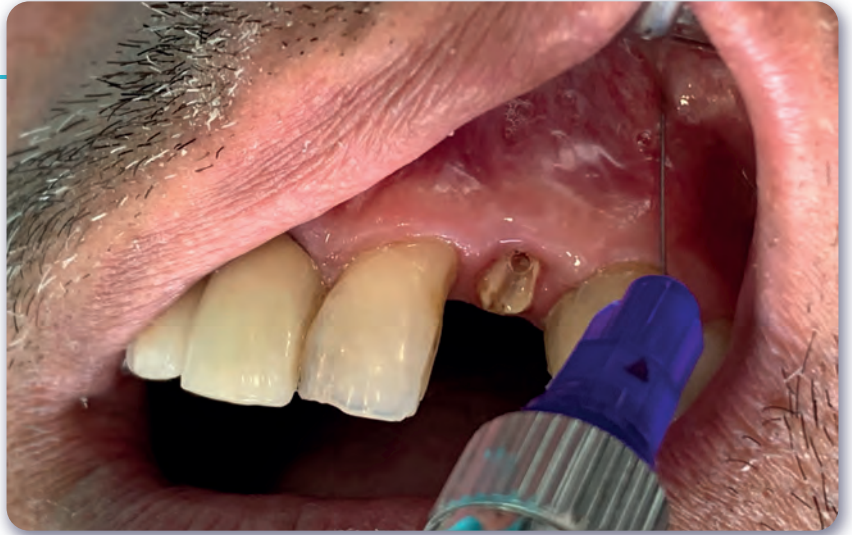1 - 3

Broken root
Maxillary left lateral incisor



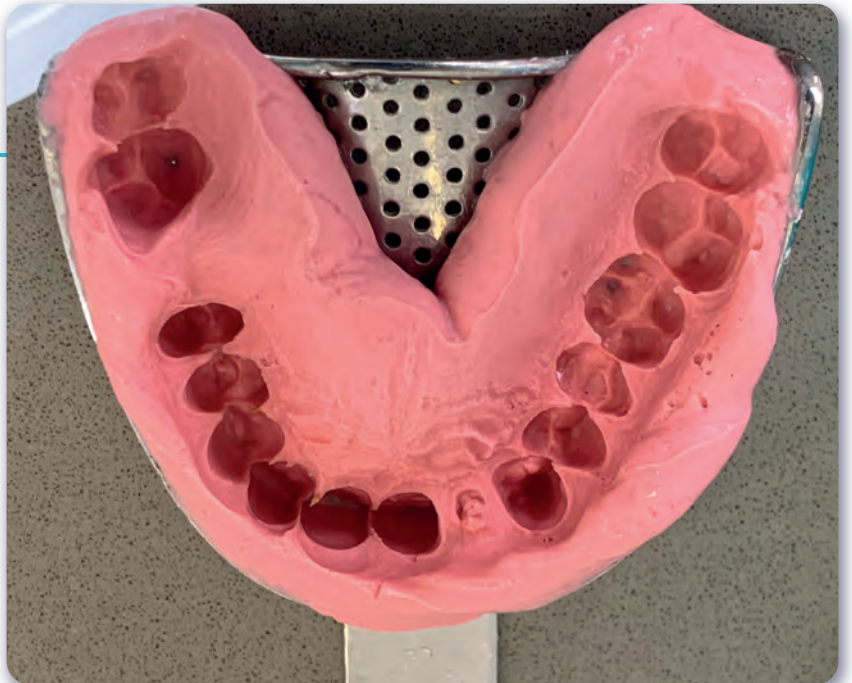
4

Local anesthetics



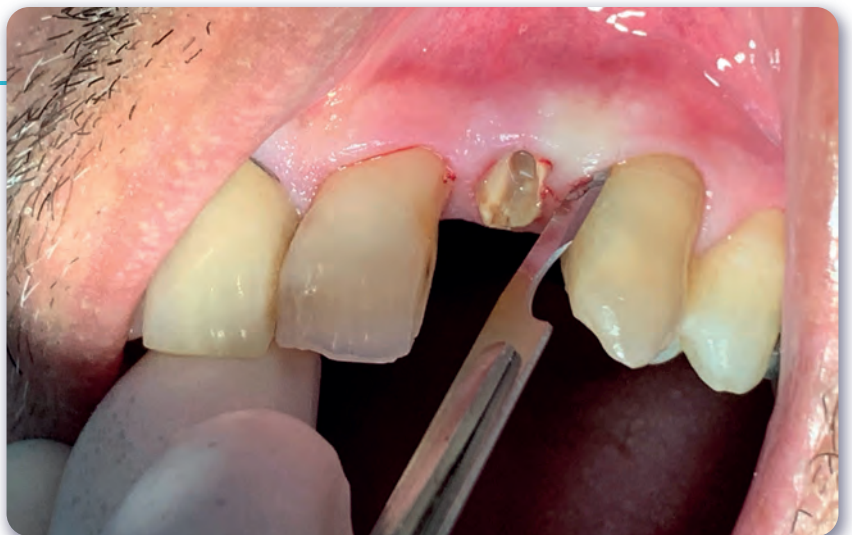5

Impression for temporary



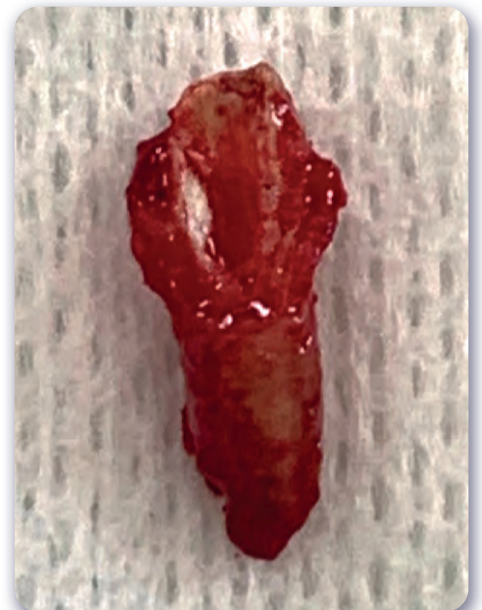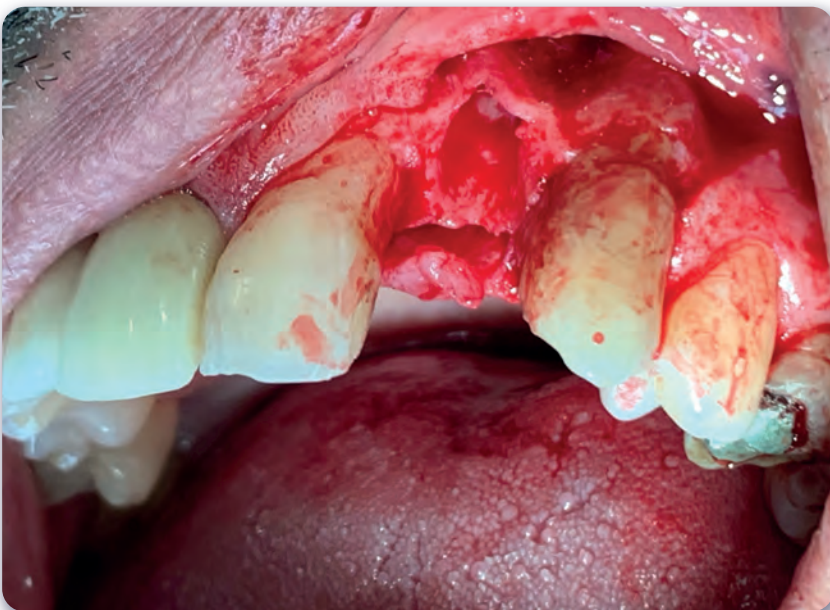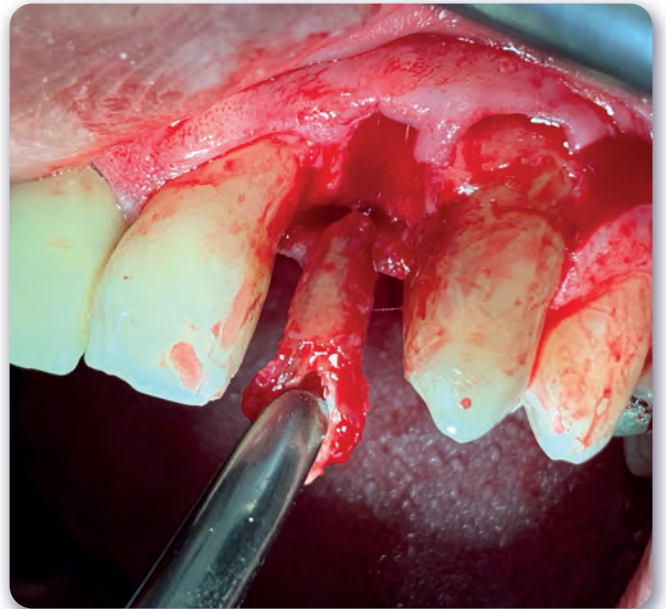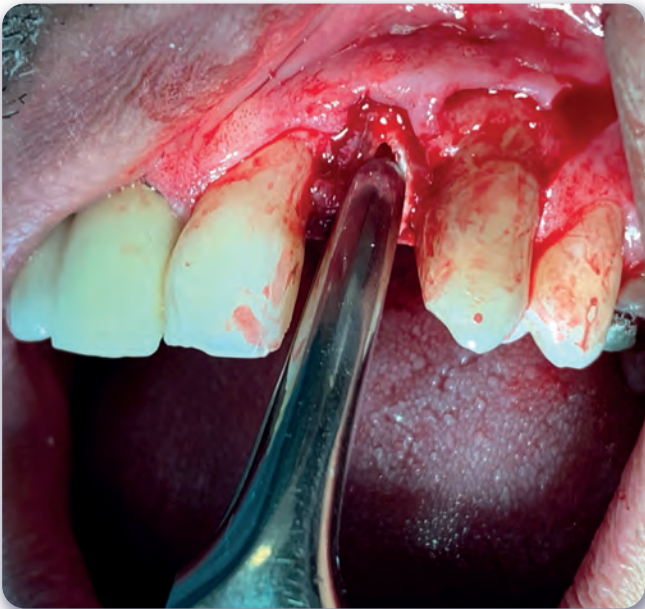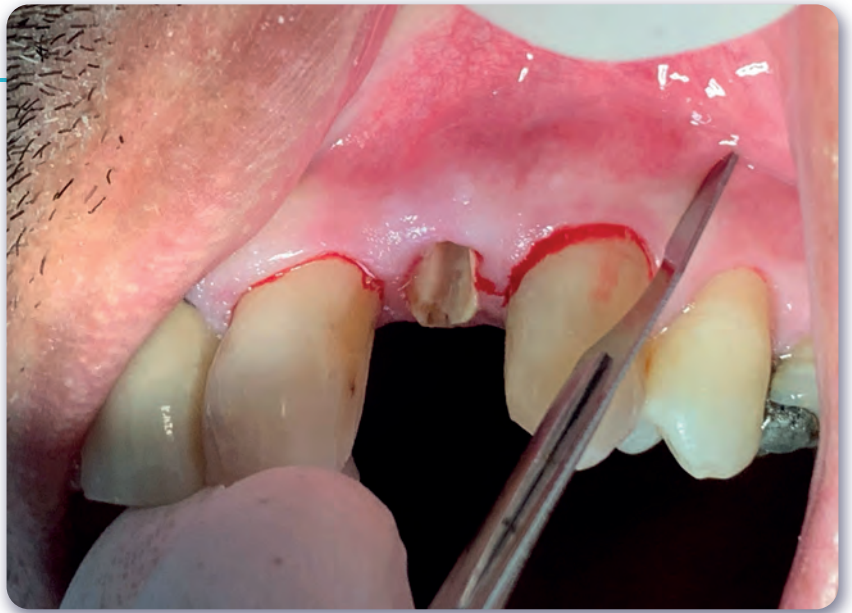6

Incision



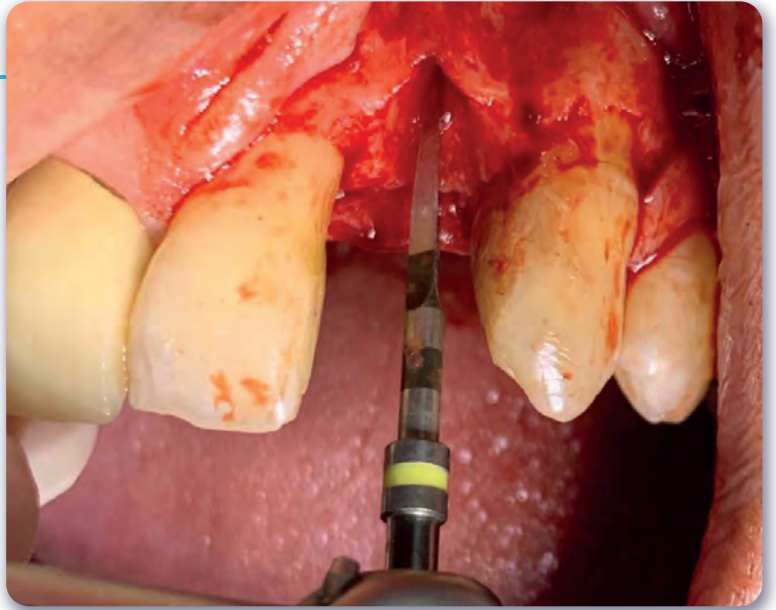
7 - 11

Flap elevation & extraction



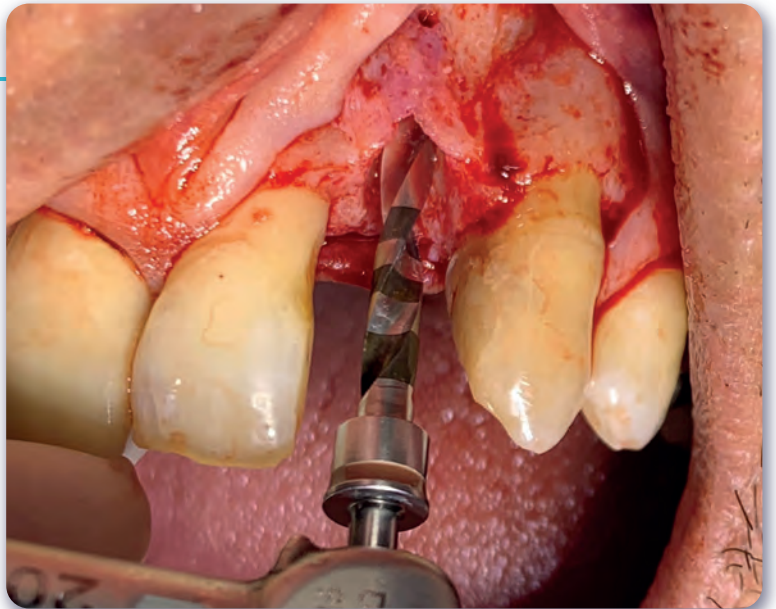
12

Pilot drill



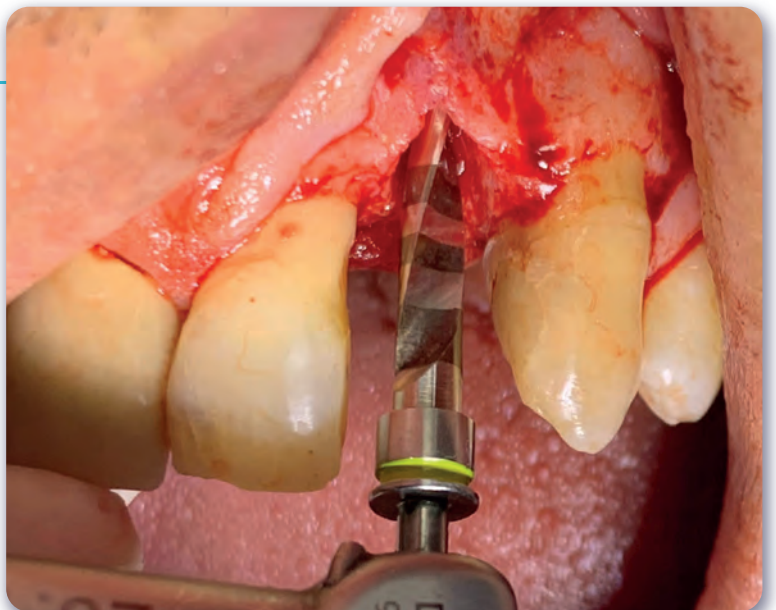
13

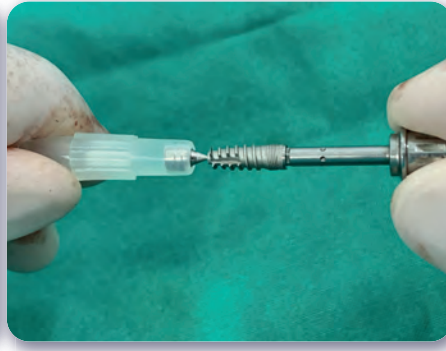
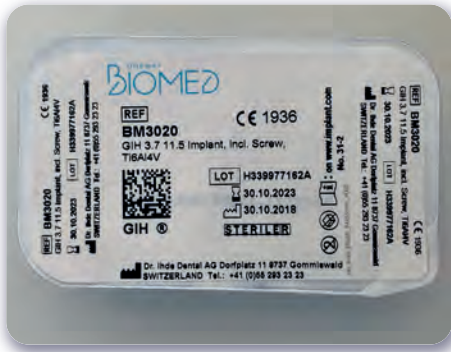Drill 1



14

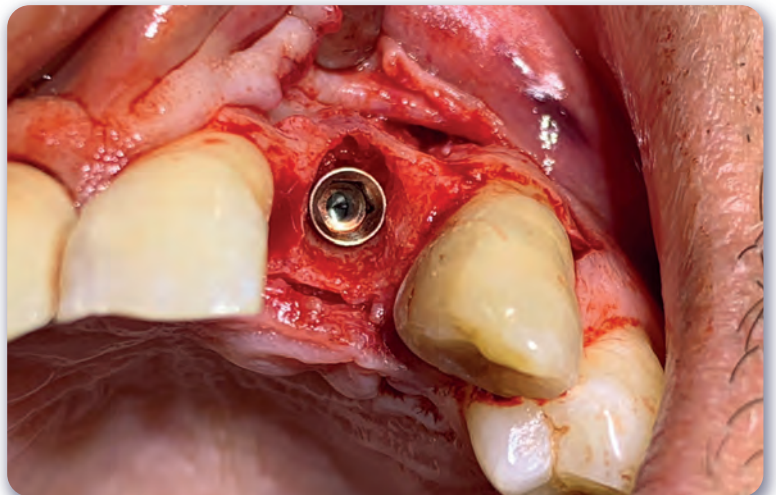
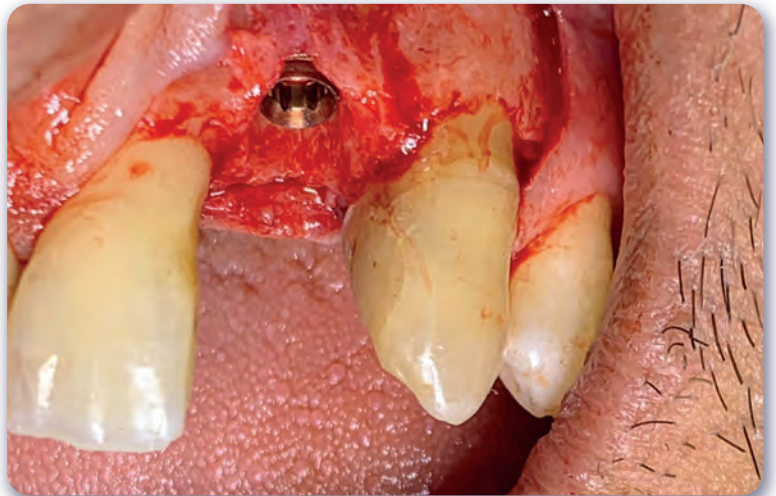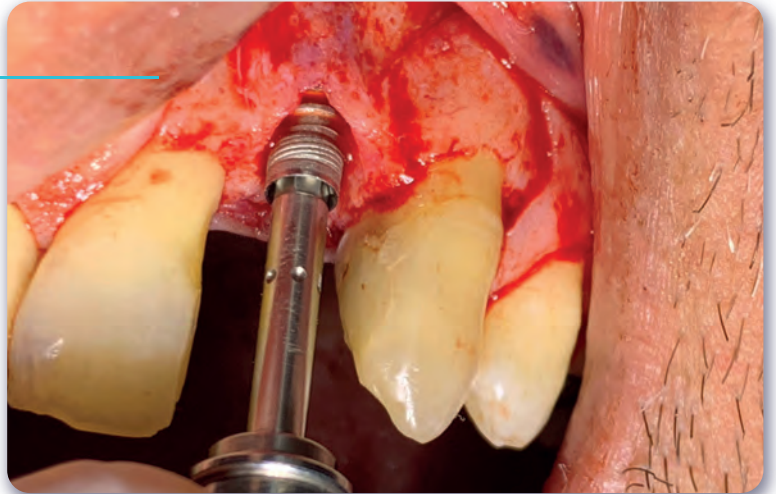
Drill 2





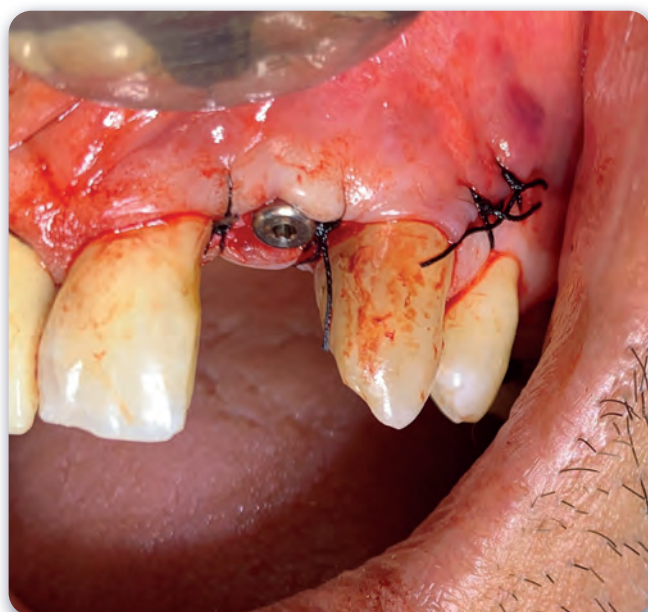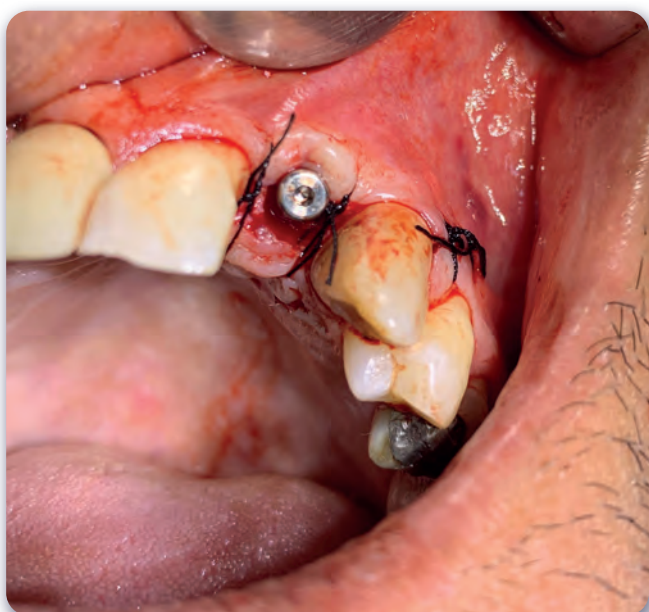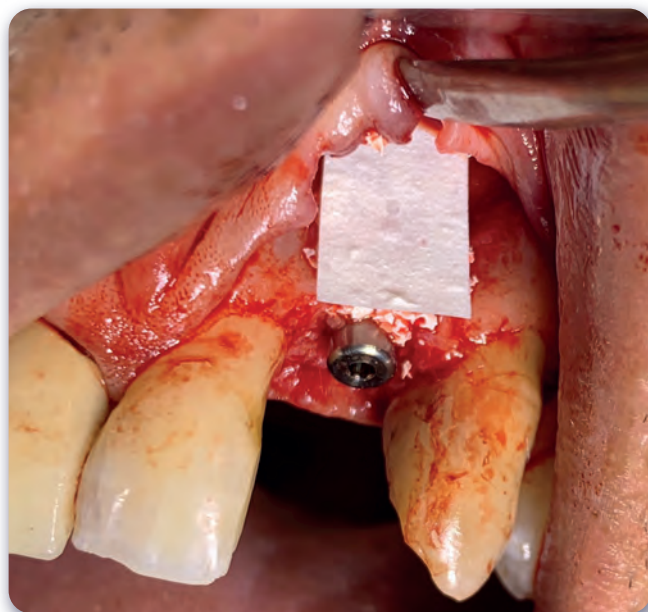
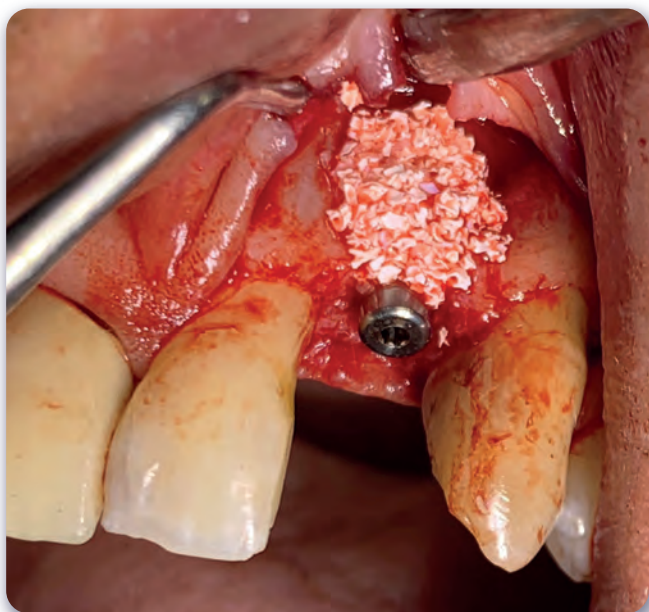
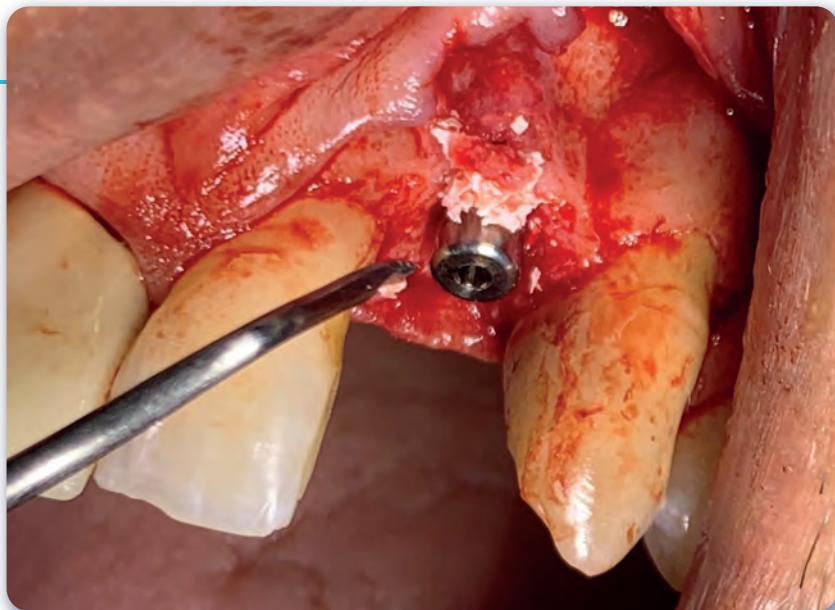
16 - 18

Implant insertion

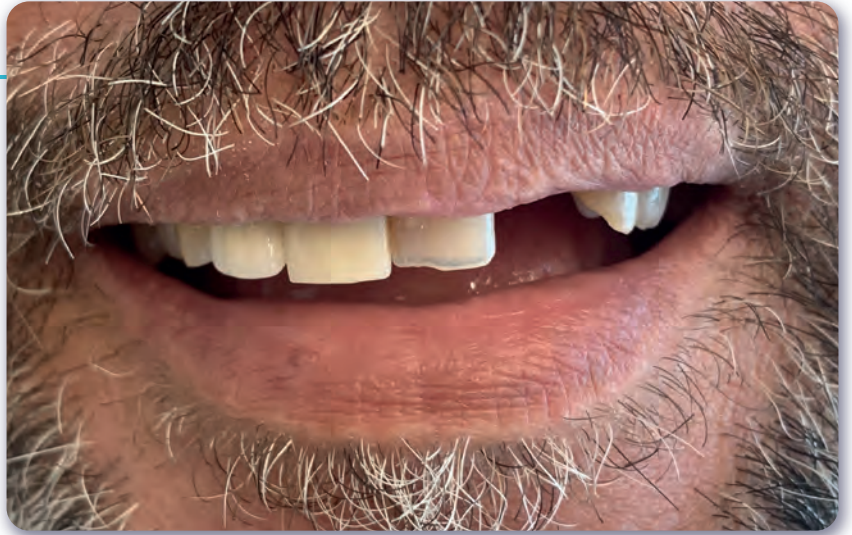

19 - 23

Bone grafting procedure



24



25

Temporary tray in place

